

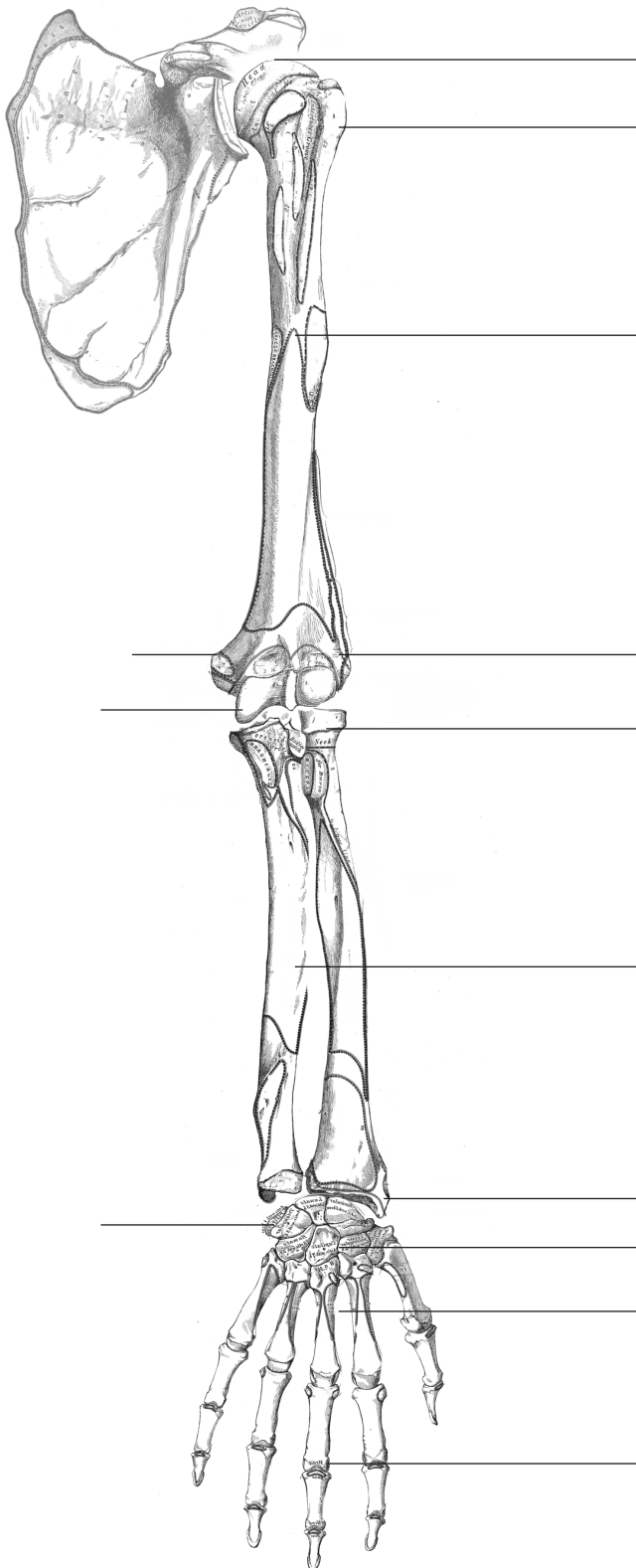
# Anatomy

## Month Three

S.S.O.M.A.

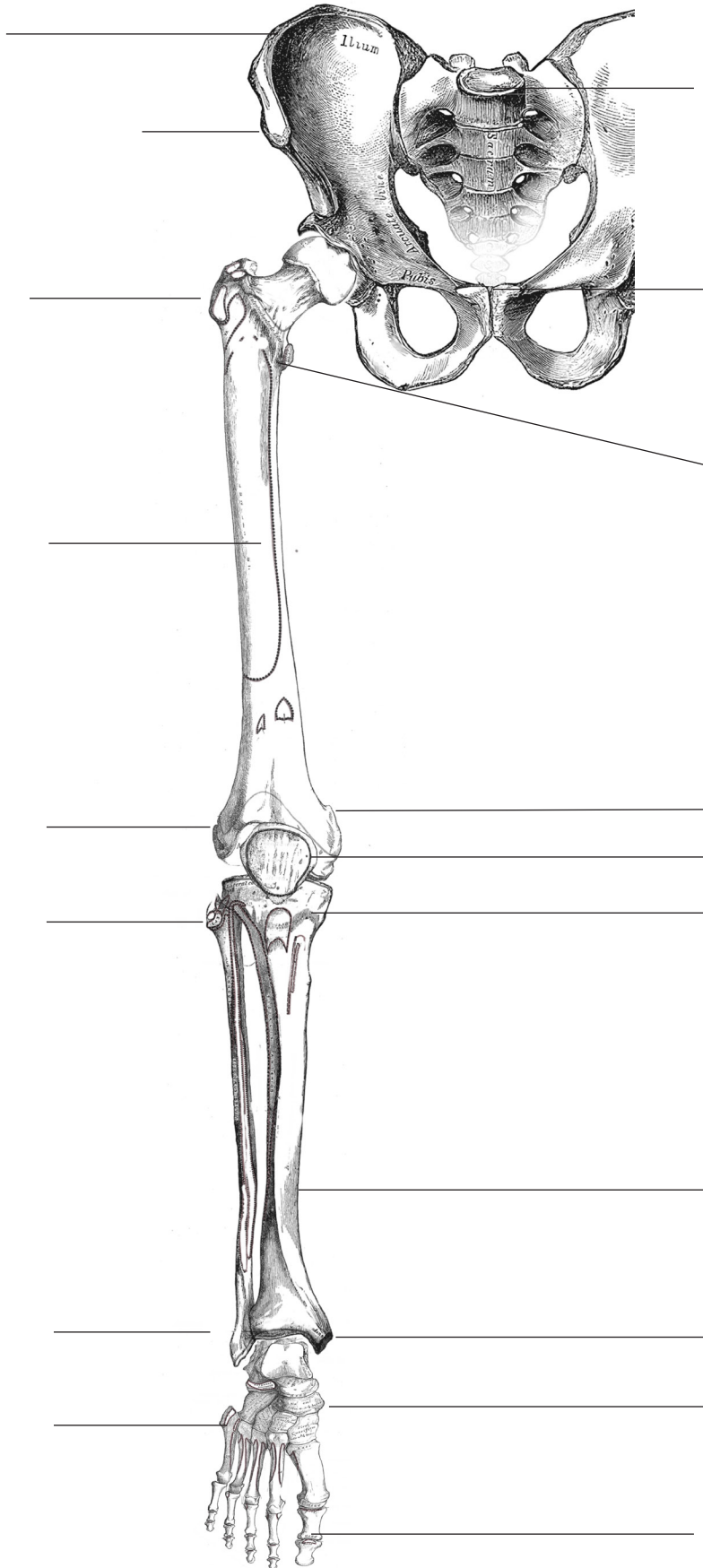
What are main bones and landmarks of upper limb?

90% pass mark



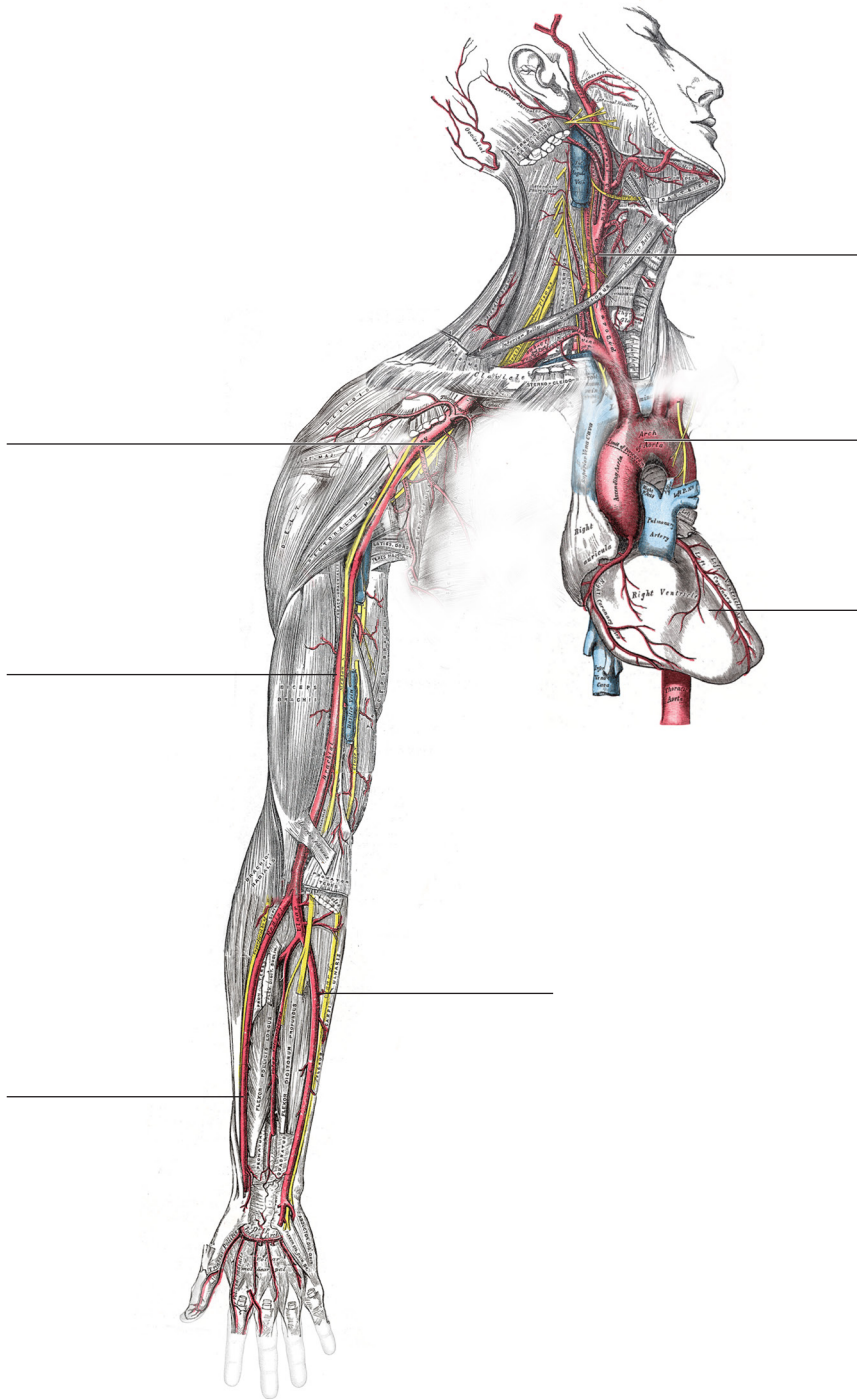
What are main bones and landmarks of upper limb?

90% pass mark



Name these arteries (heart channel)

90% pass mark

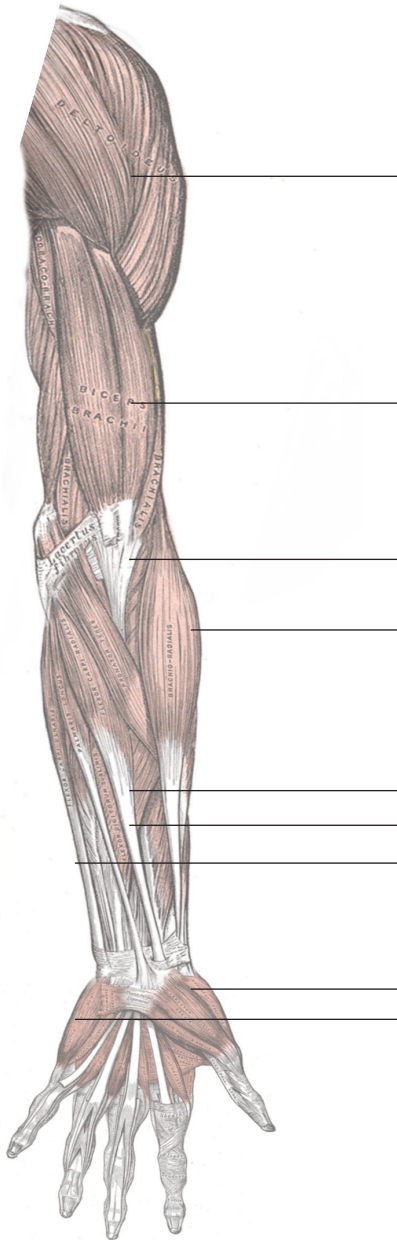


The heart channel and major arteries above the diaphragm are the exact same thing.

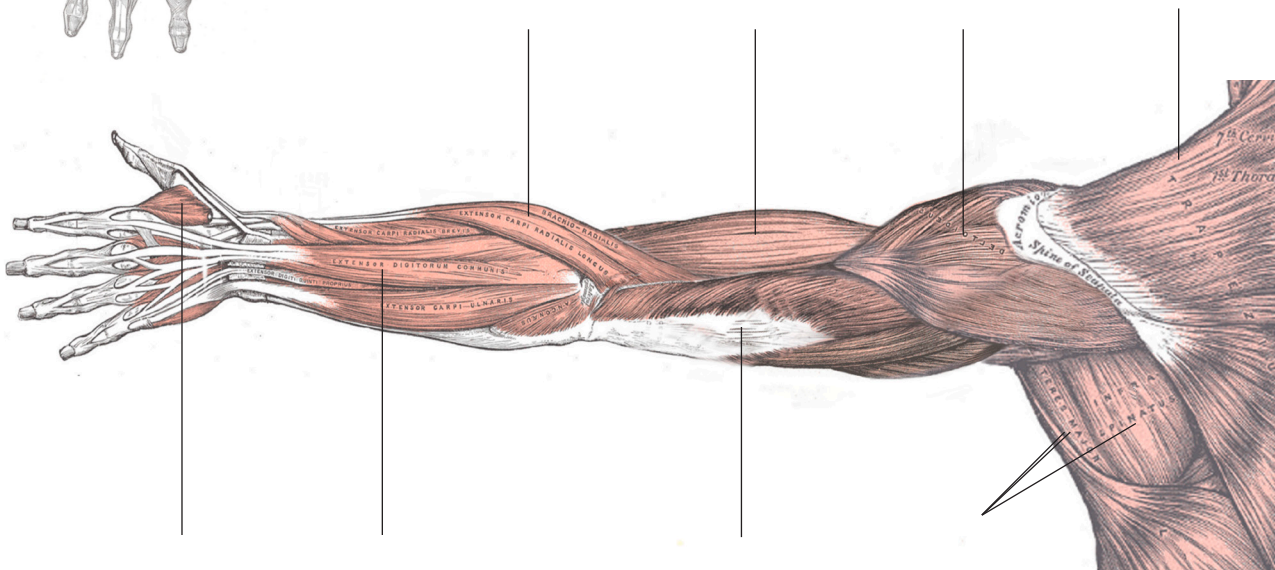
**FRONT OF ARM  
(anterior / volar)**

Muscles of Arms

90% pass mark

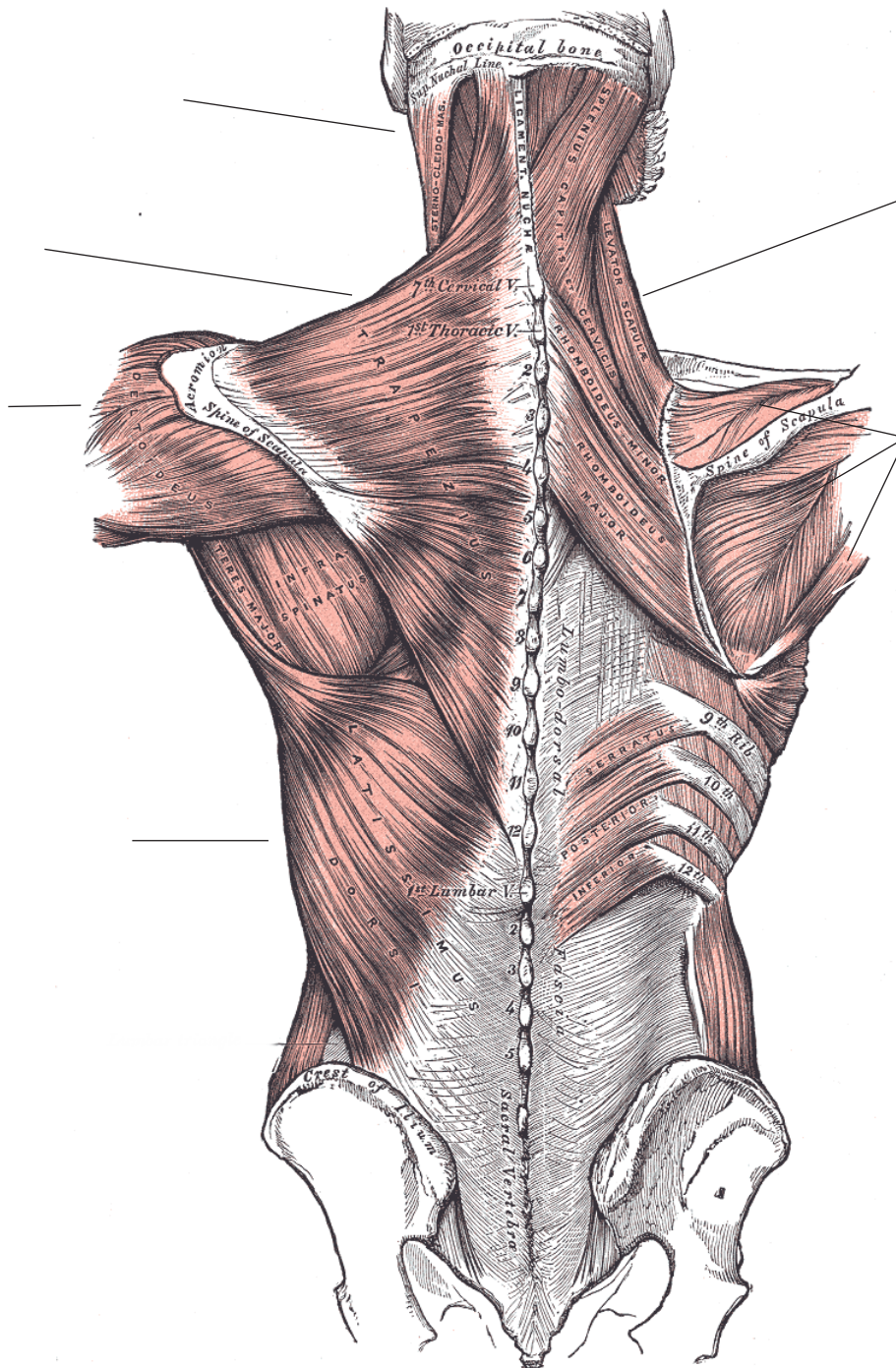


**BACK OF ARM  
(posterior / dorsum)**



Muscles of Back

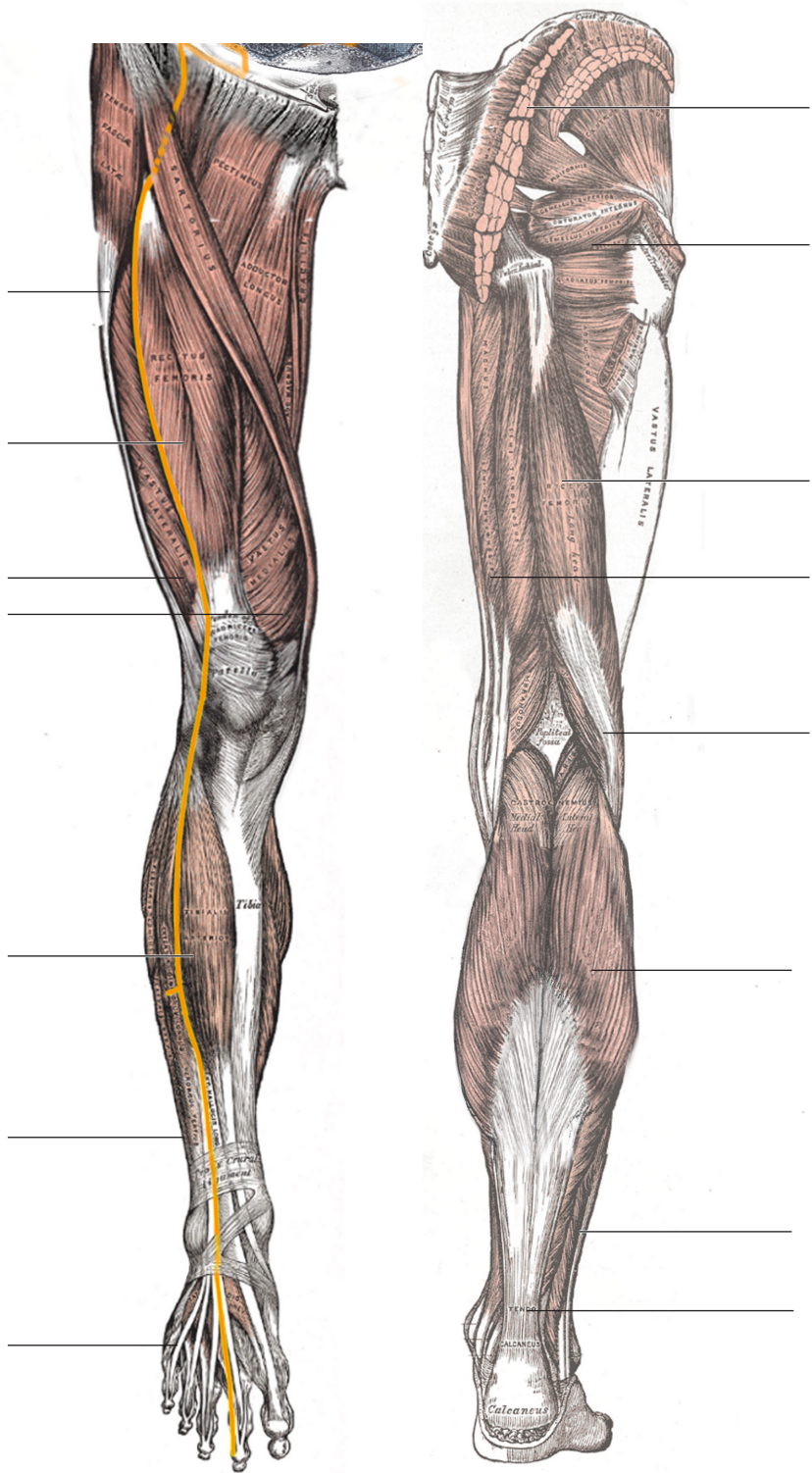
90% pass mark



Muscles of Legs  
100% pass mark

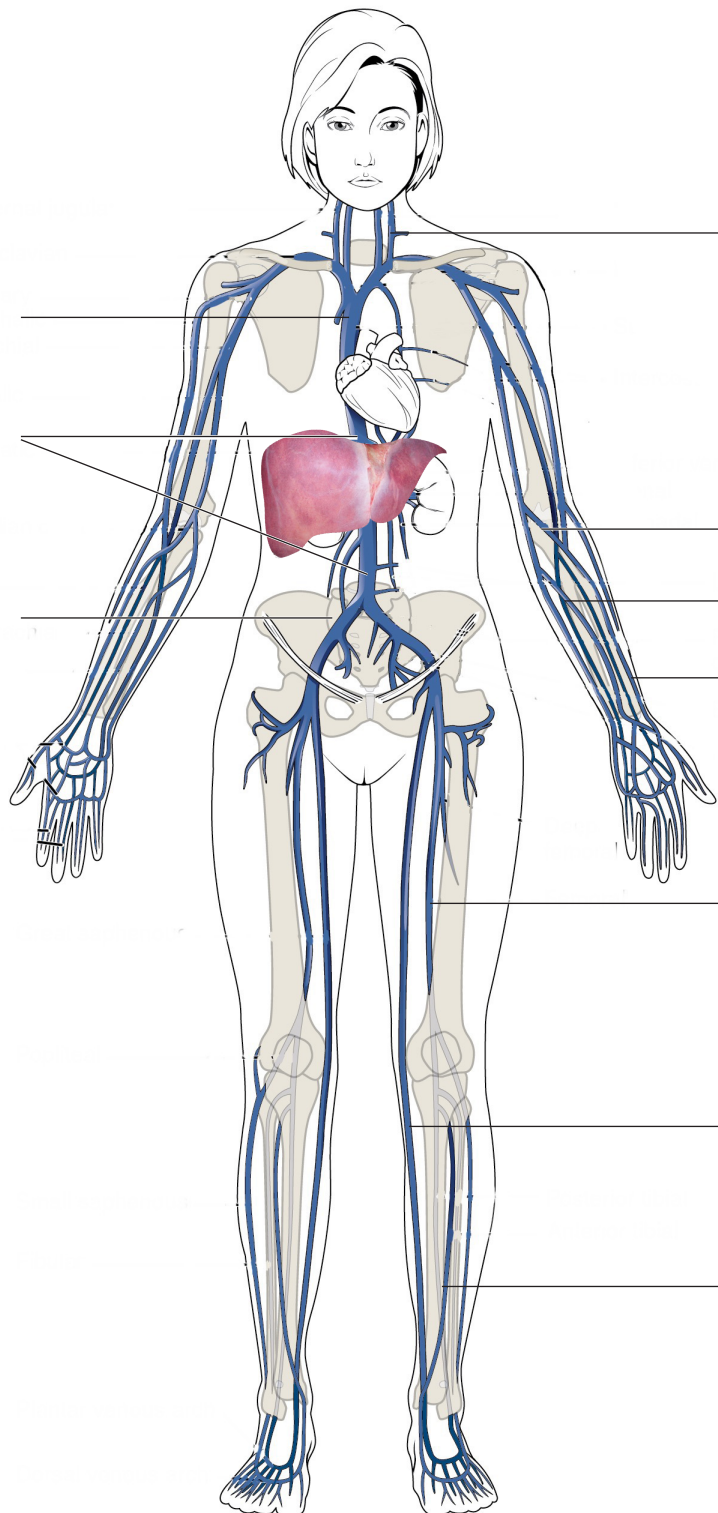
ANTERIOR

POSTERIOR



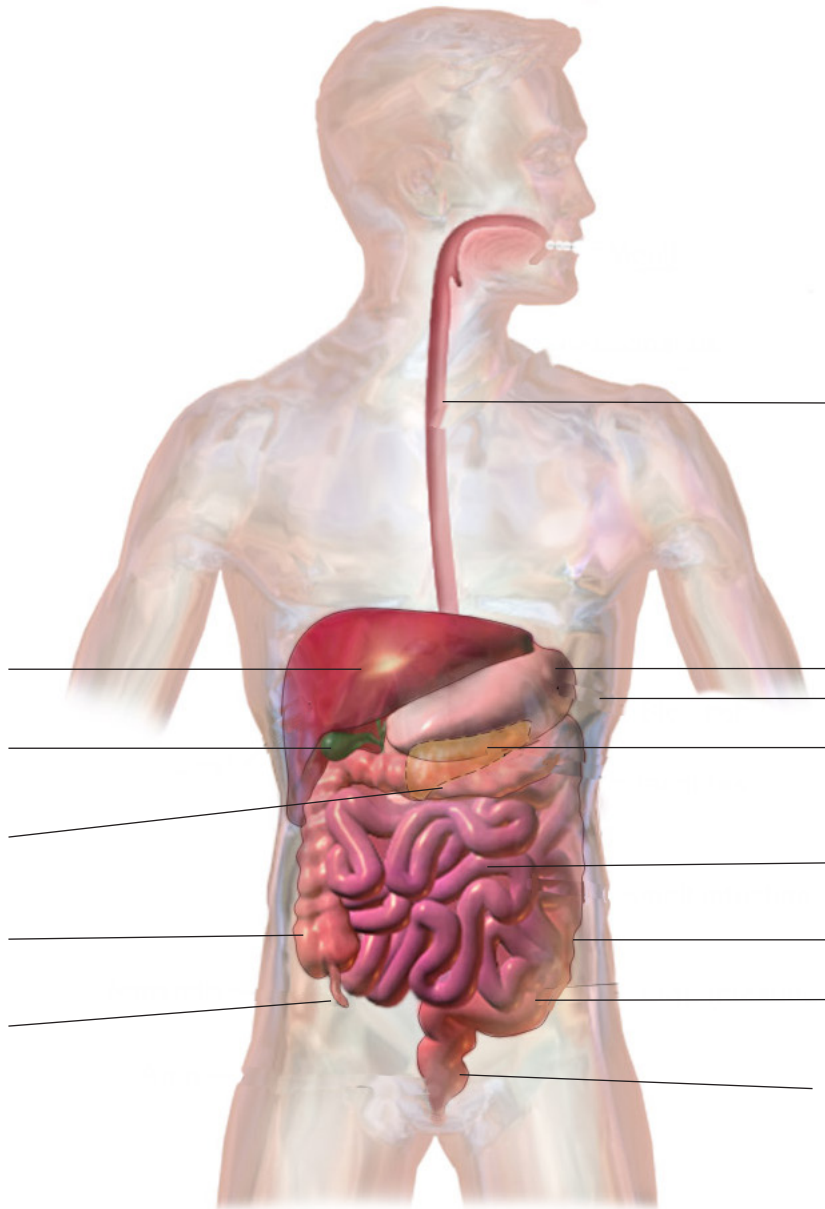
Veins of the body

100% pass mark



Veins of the body

90% pass mark



The digestive tract is a single tract which is lined by endoderm which itself is surrounded by muscle. The endoderm is taiyin, the muscle is yangming. The divisions above are essentially artificial. 13